

Caso Clínico

ANRURISMA DE CUELLO ANCHO TRATADO CON SURPASS

Historia clínica

- Edad:
- Sexo:
- Presentación clínica:

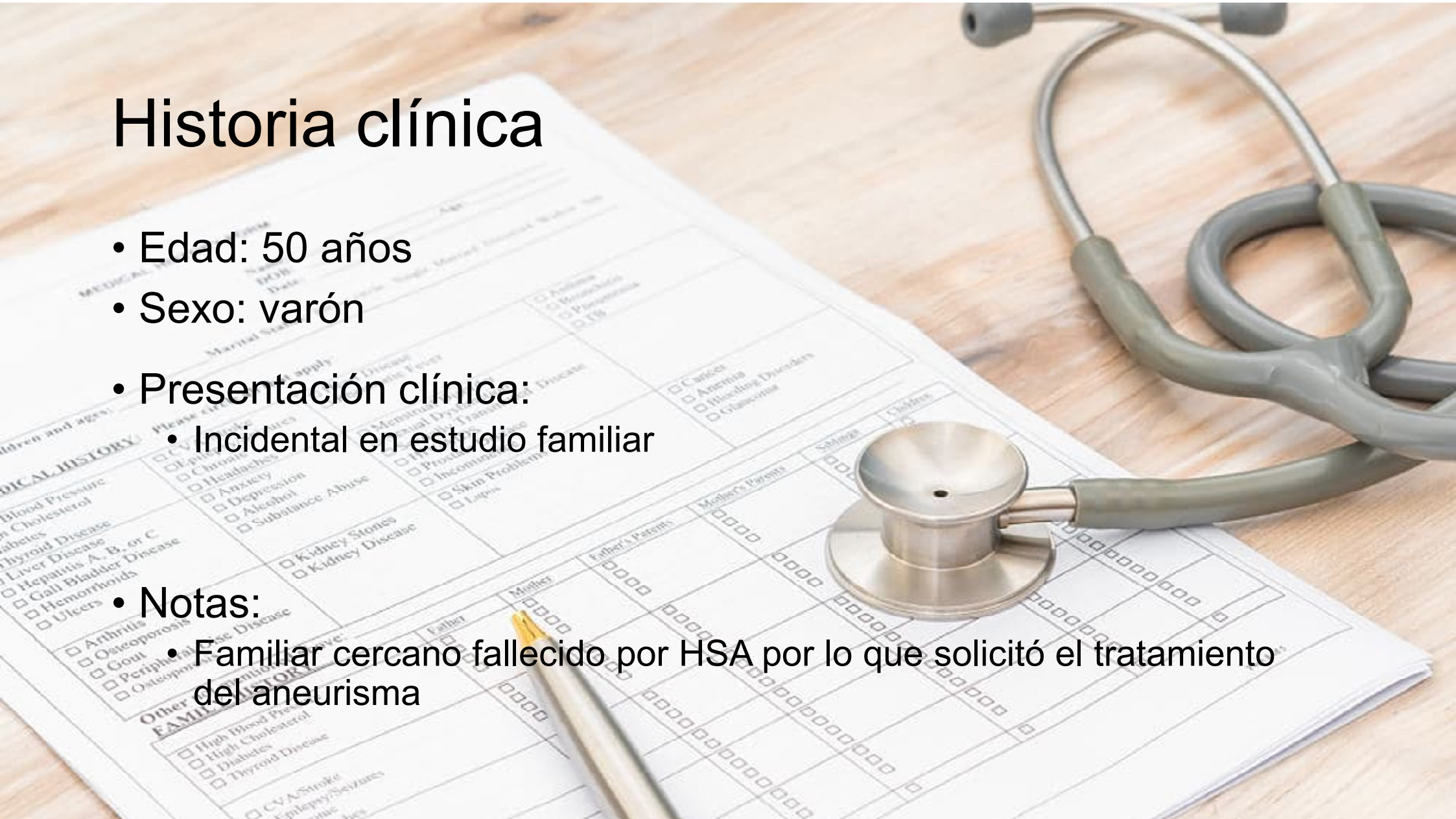
- Notas

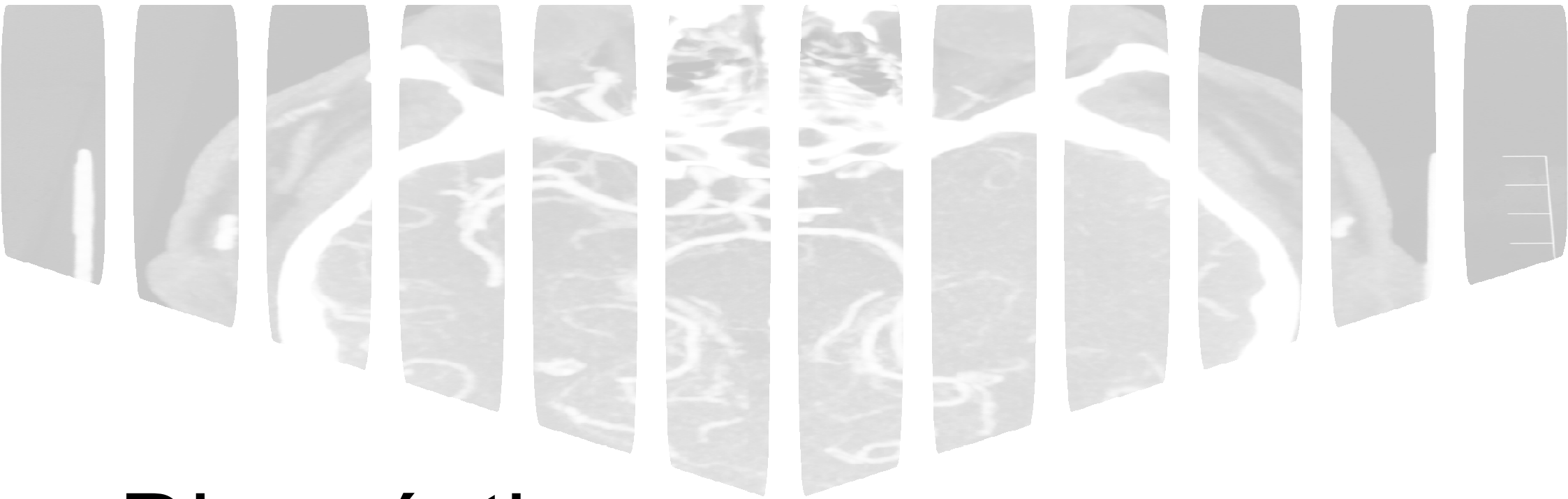


Procedimiento

Historia clínica

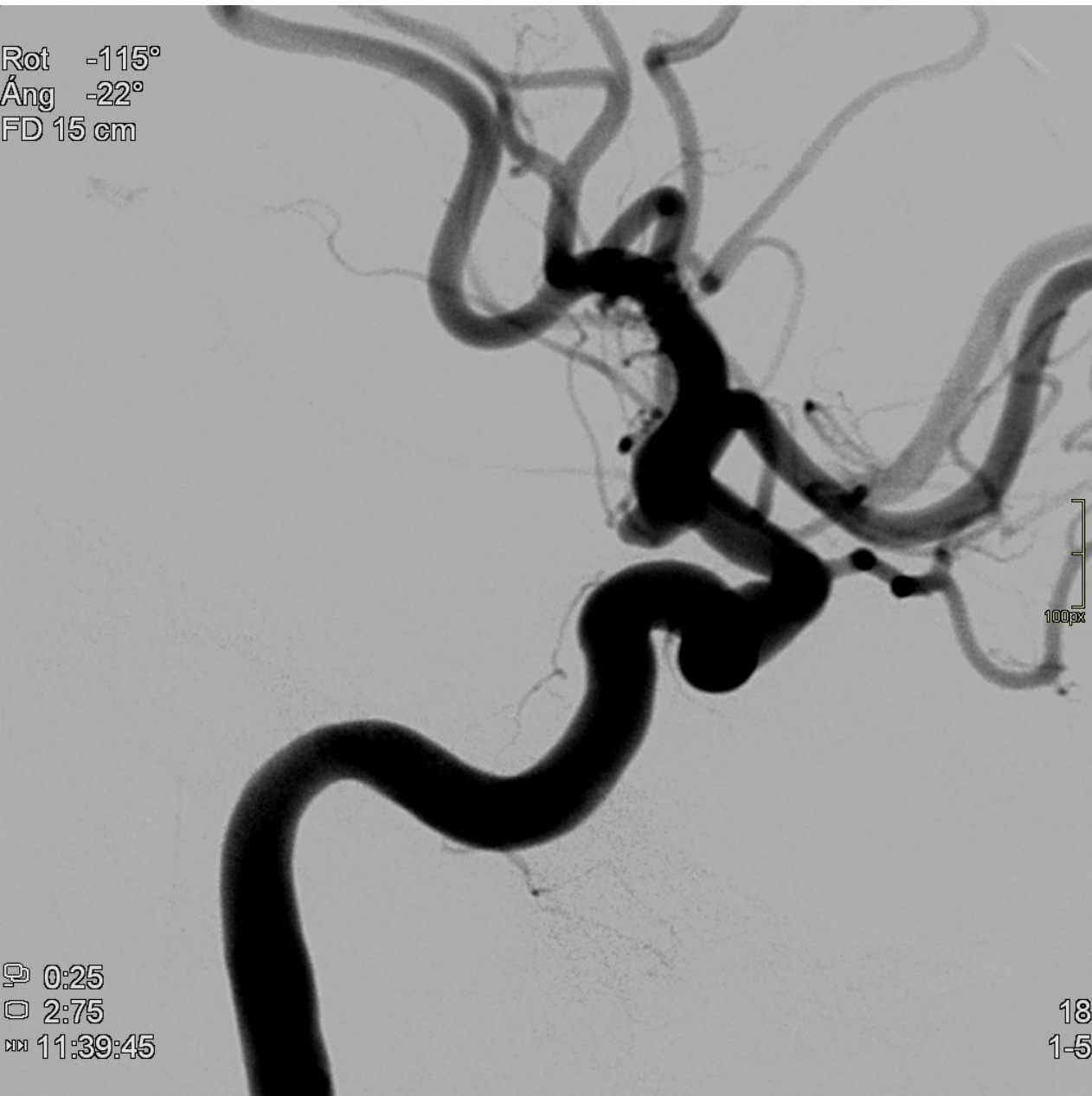
- Edad: 50 años
- Sexo: varón
- Presentación clínica:
 - Incidental en estudio familiar
- Notas:
 - Familiar cercano fallecido por HSA por lo que solicitó el tratamiento del aneurisma





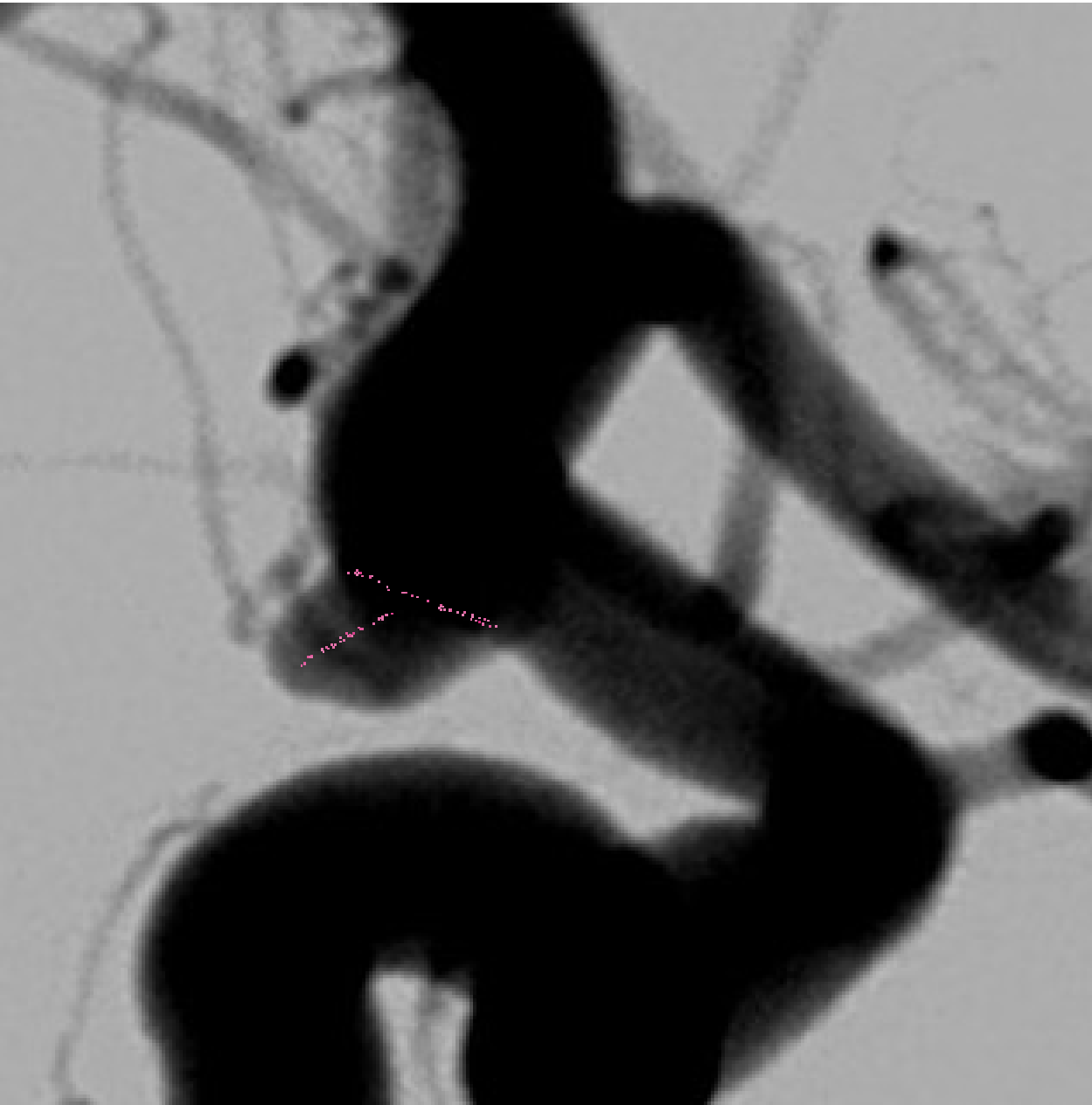
Diagnóstico

Rot -115°
Áng -22°
FD 15 cm

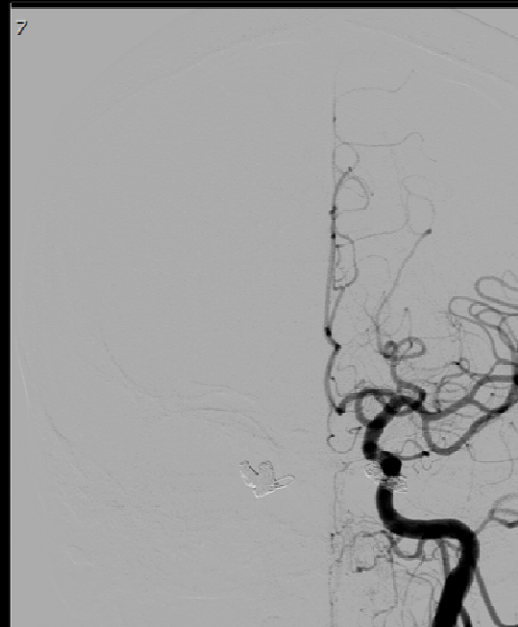
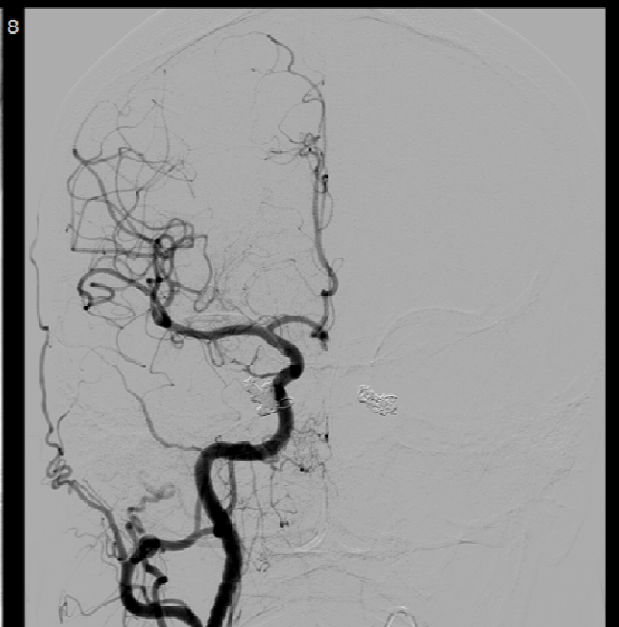
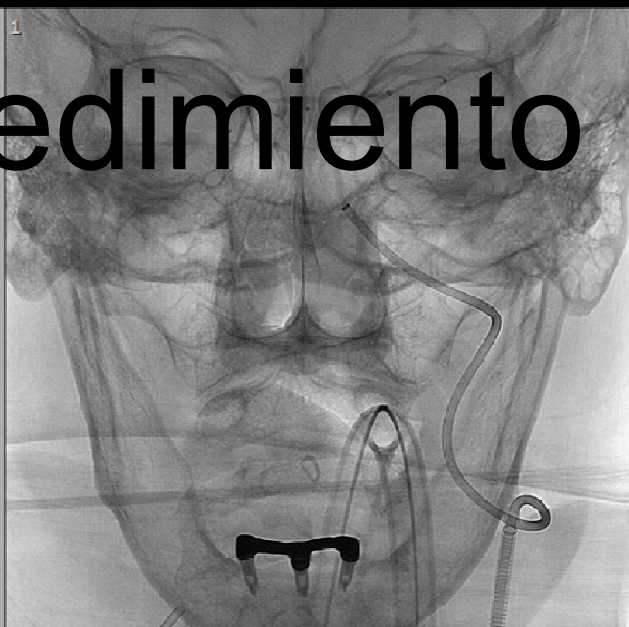
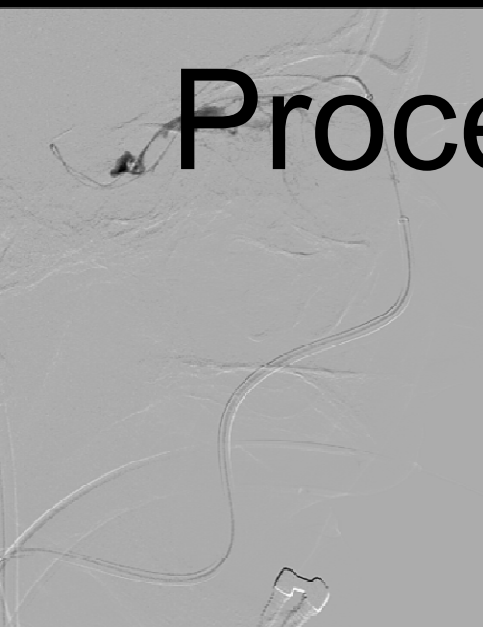
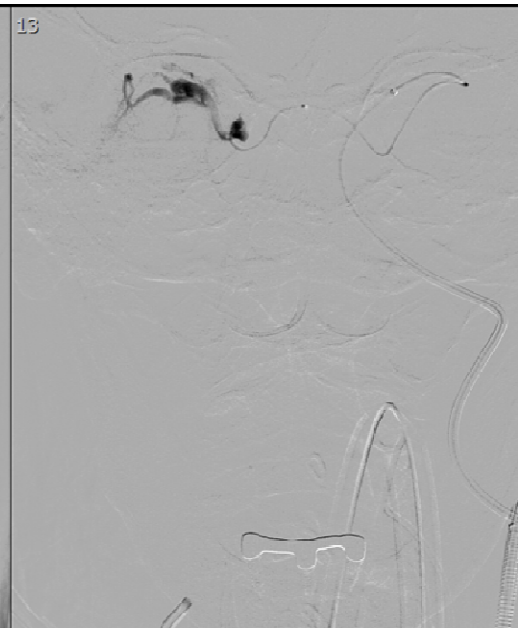
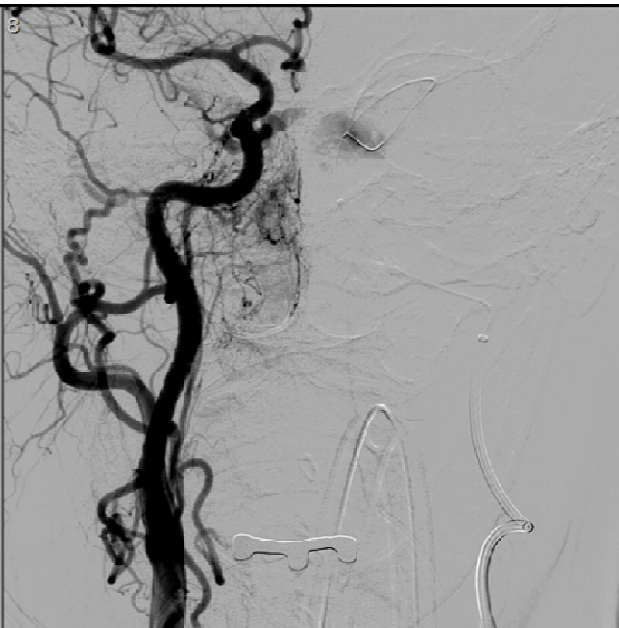
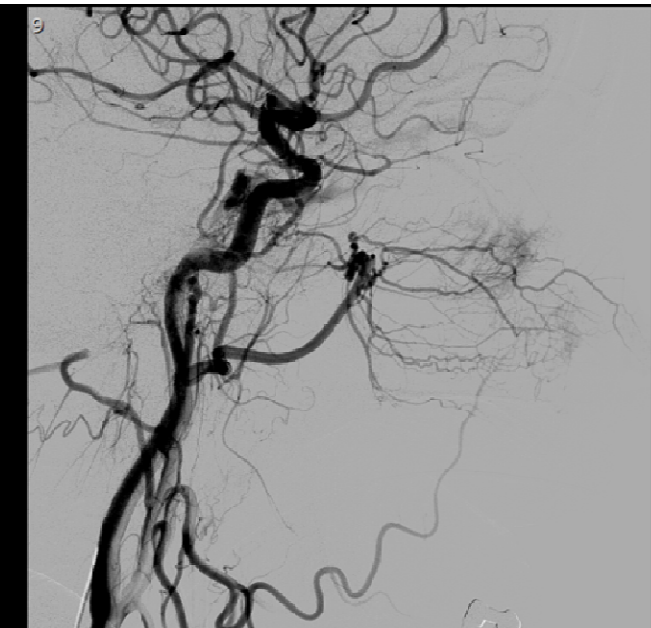
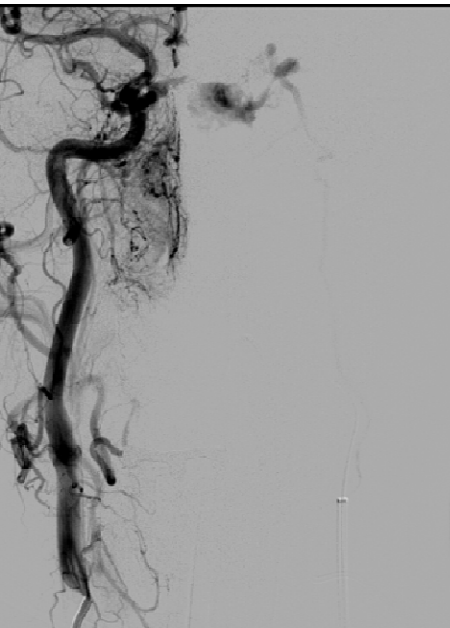


0:25
2:75
11:39:45

18
1-5

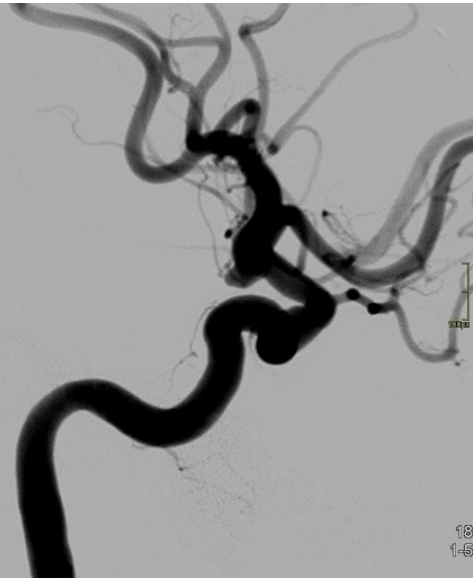


Aneurisma de 5 mm de tamaño con cuello de 5 mm



Procedimiento

Rot -115°
Ang -22°
FD 15 cm



0:25
2:75
11:39:45

18
1-5

Rot -11°
Áng +19°
FD 15 cm

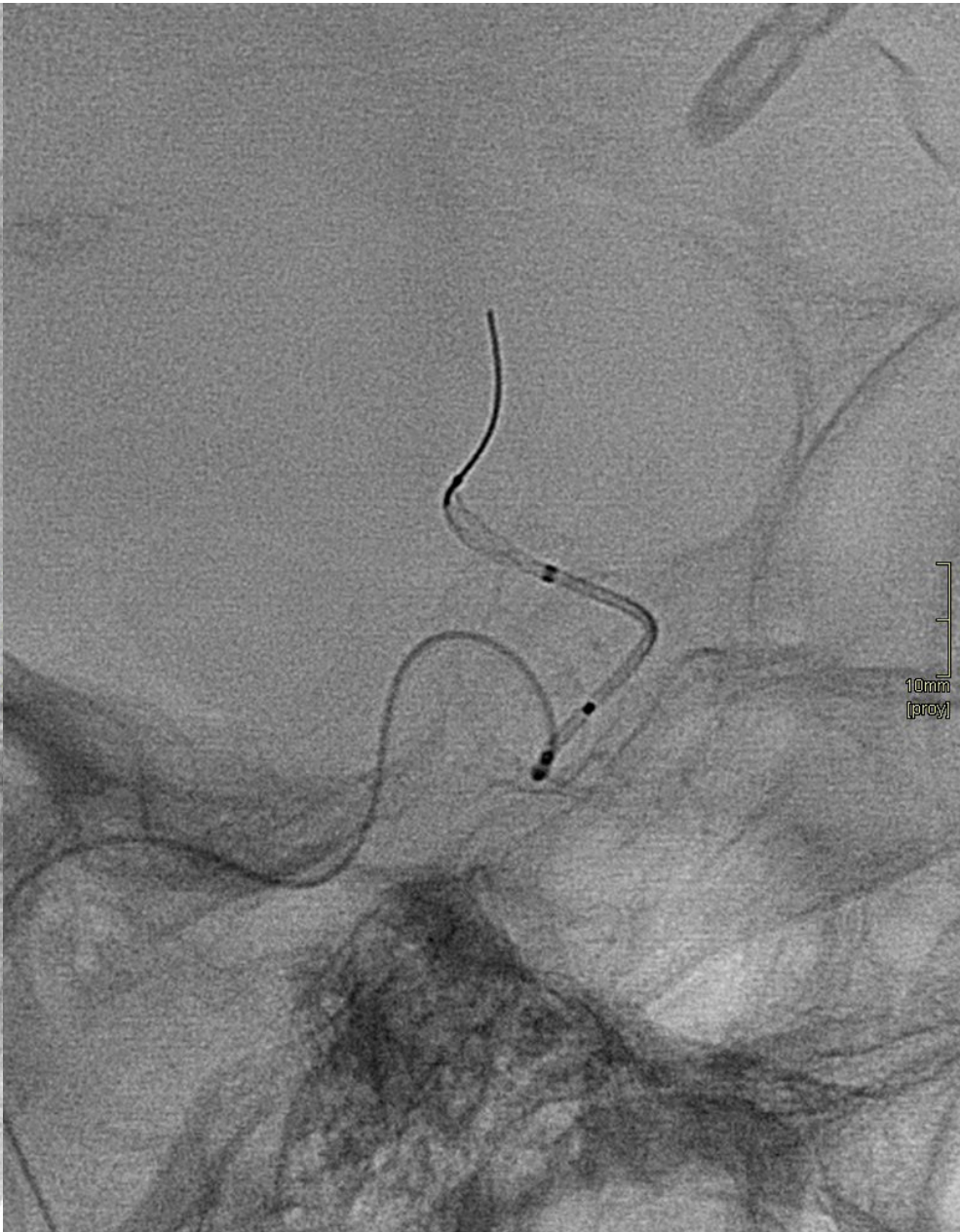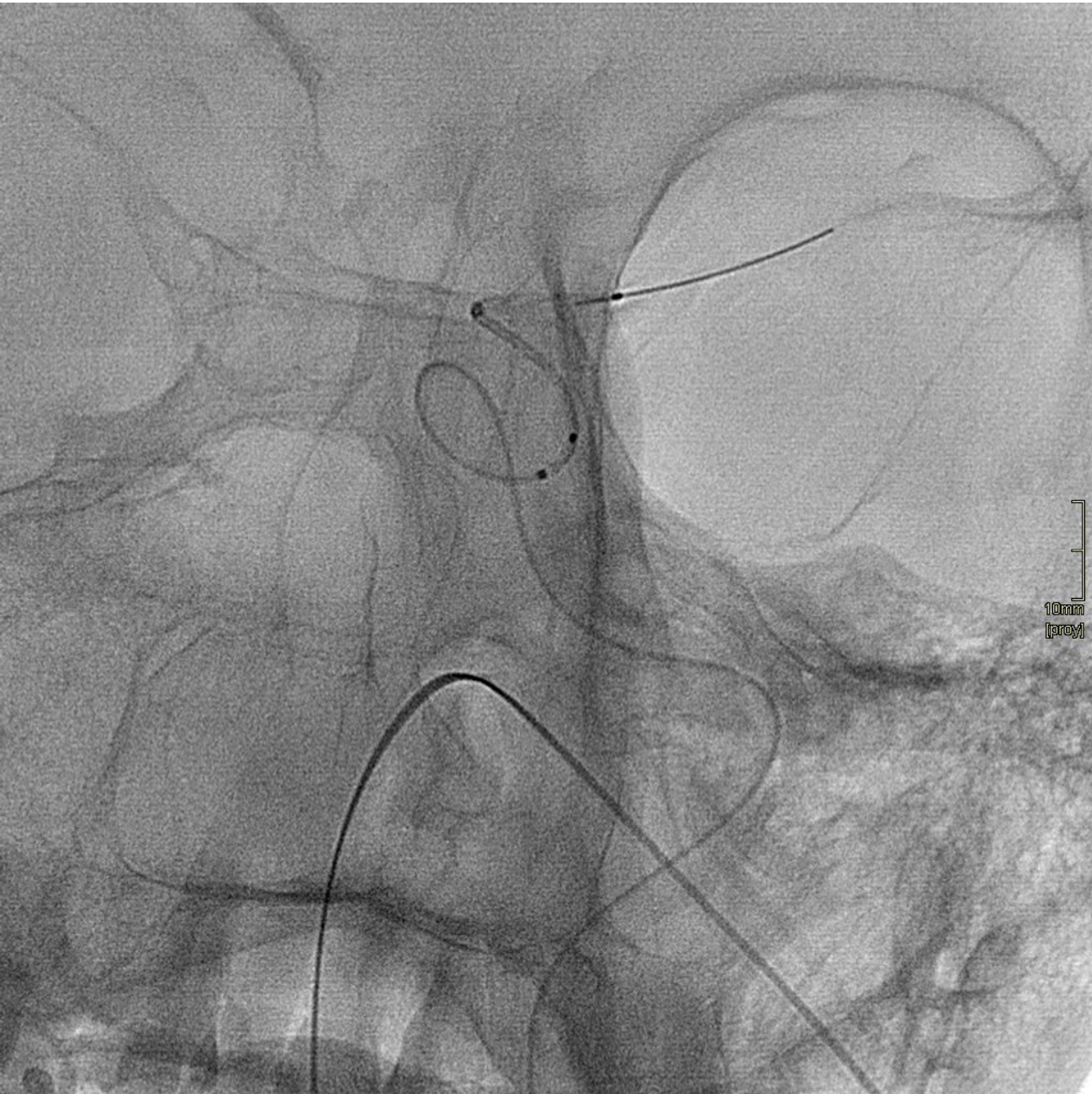
Rot -115°
Áng -22°
FD 15 cm

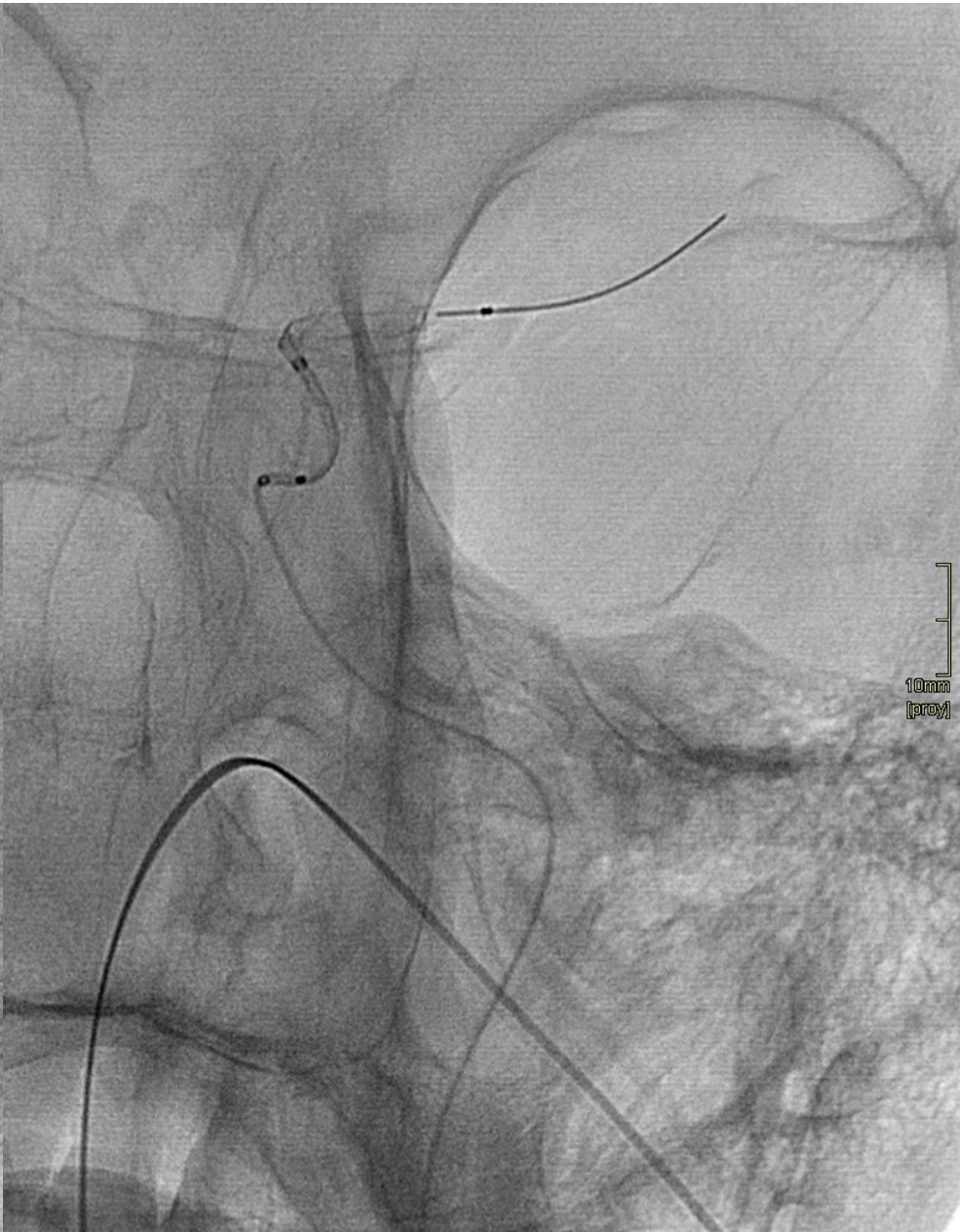
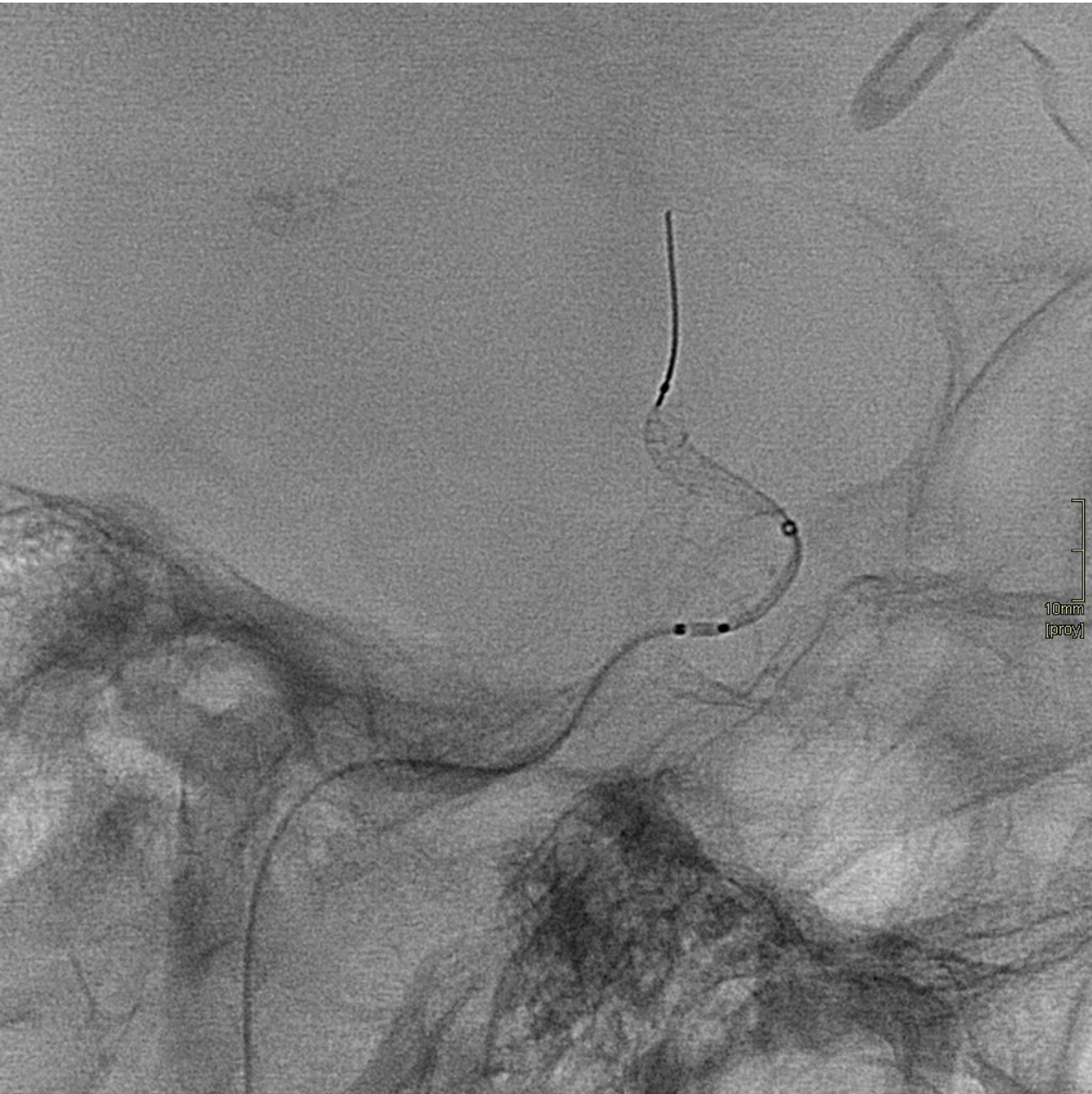


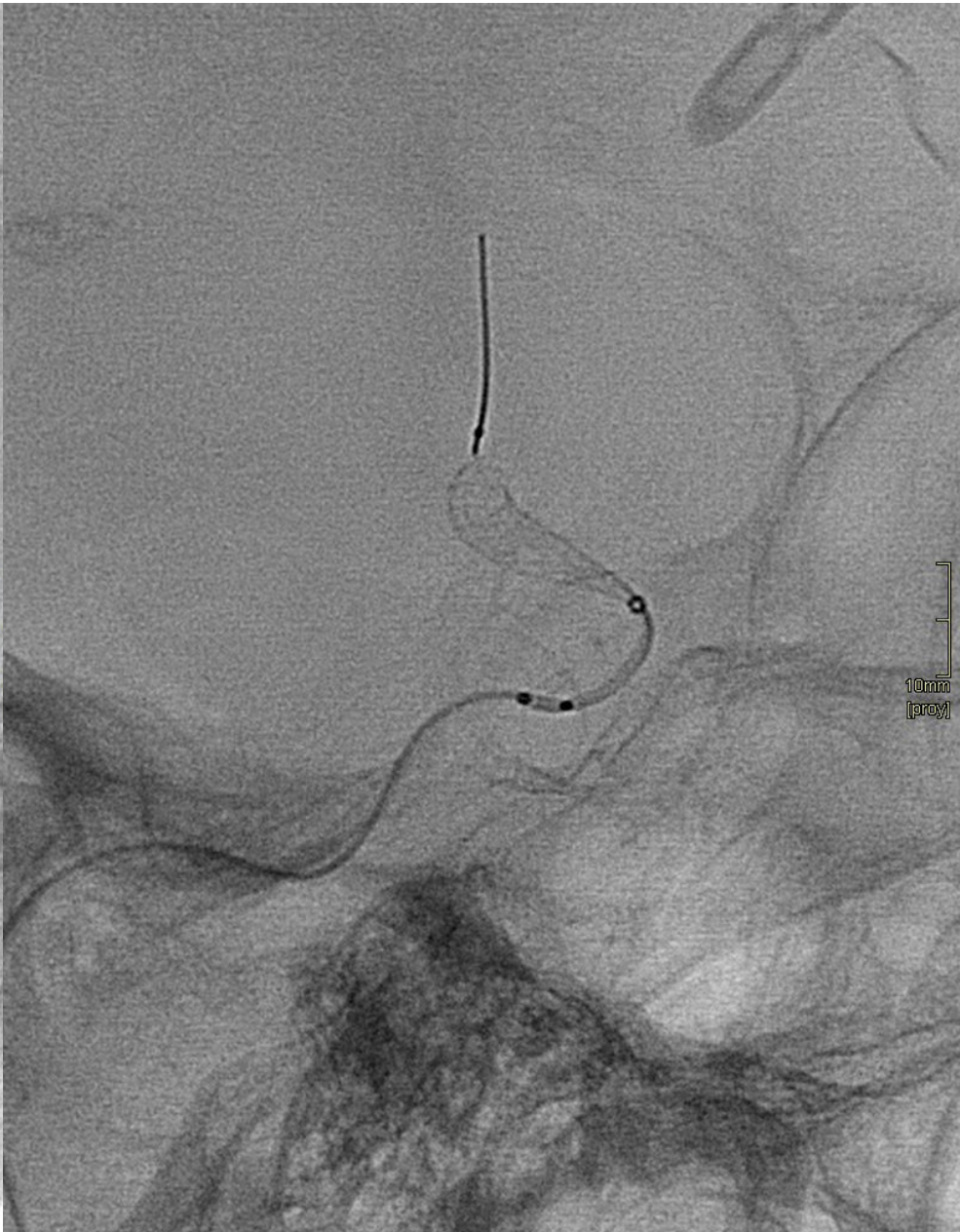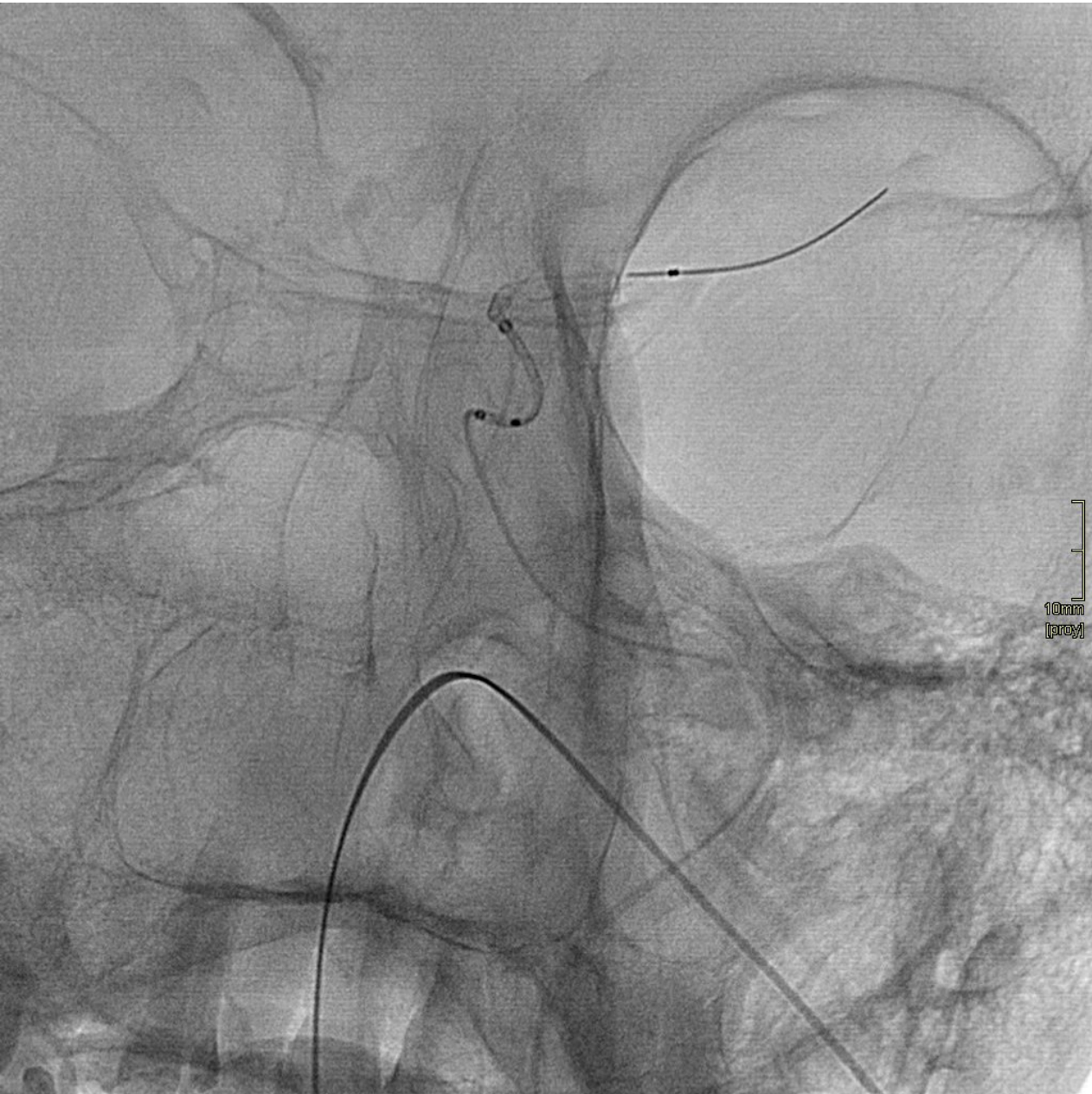
📄 19:87
🕒 0:00
📅 11:44:33

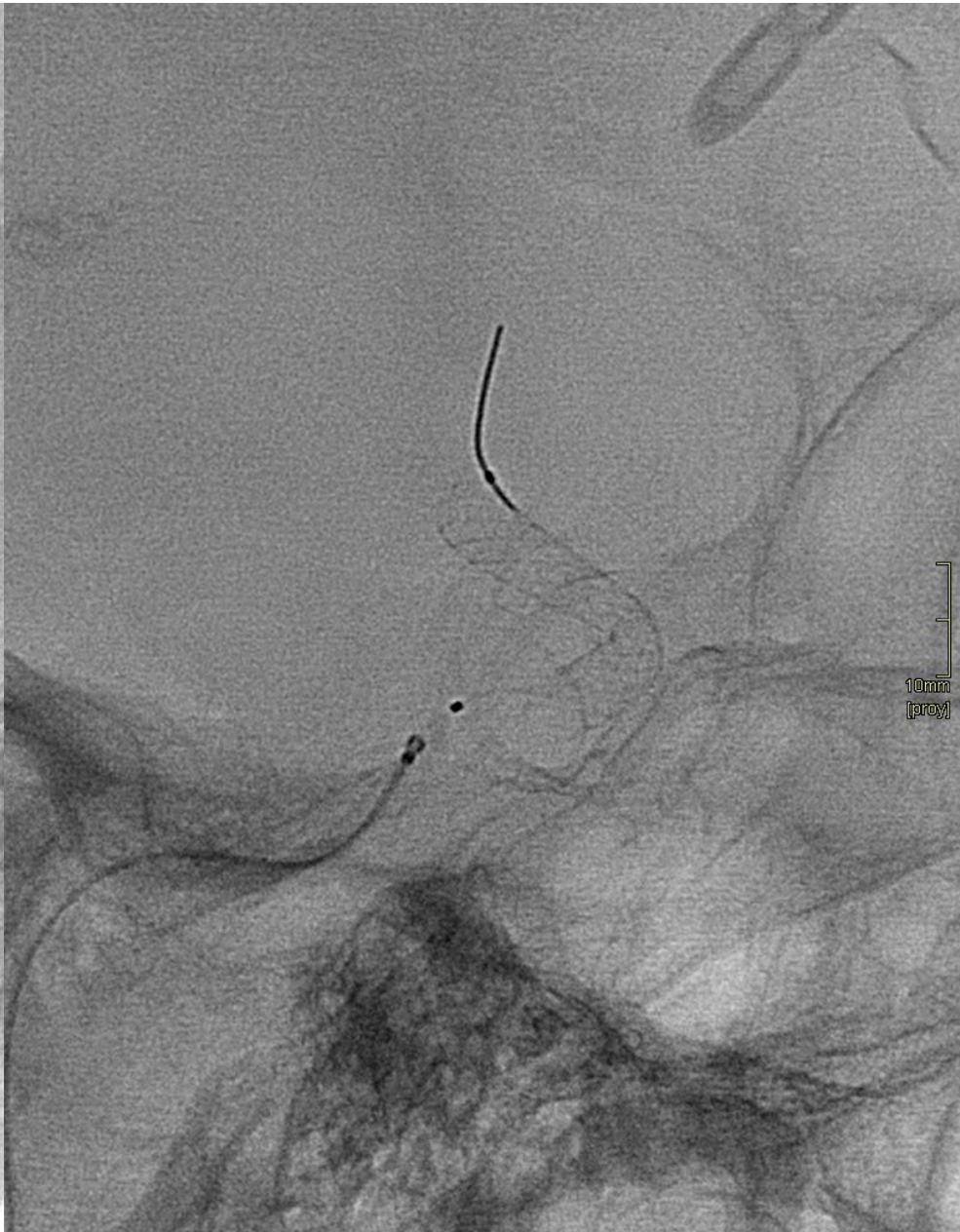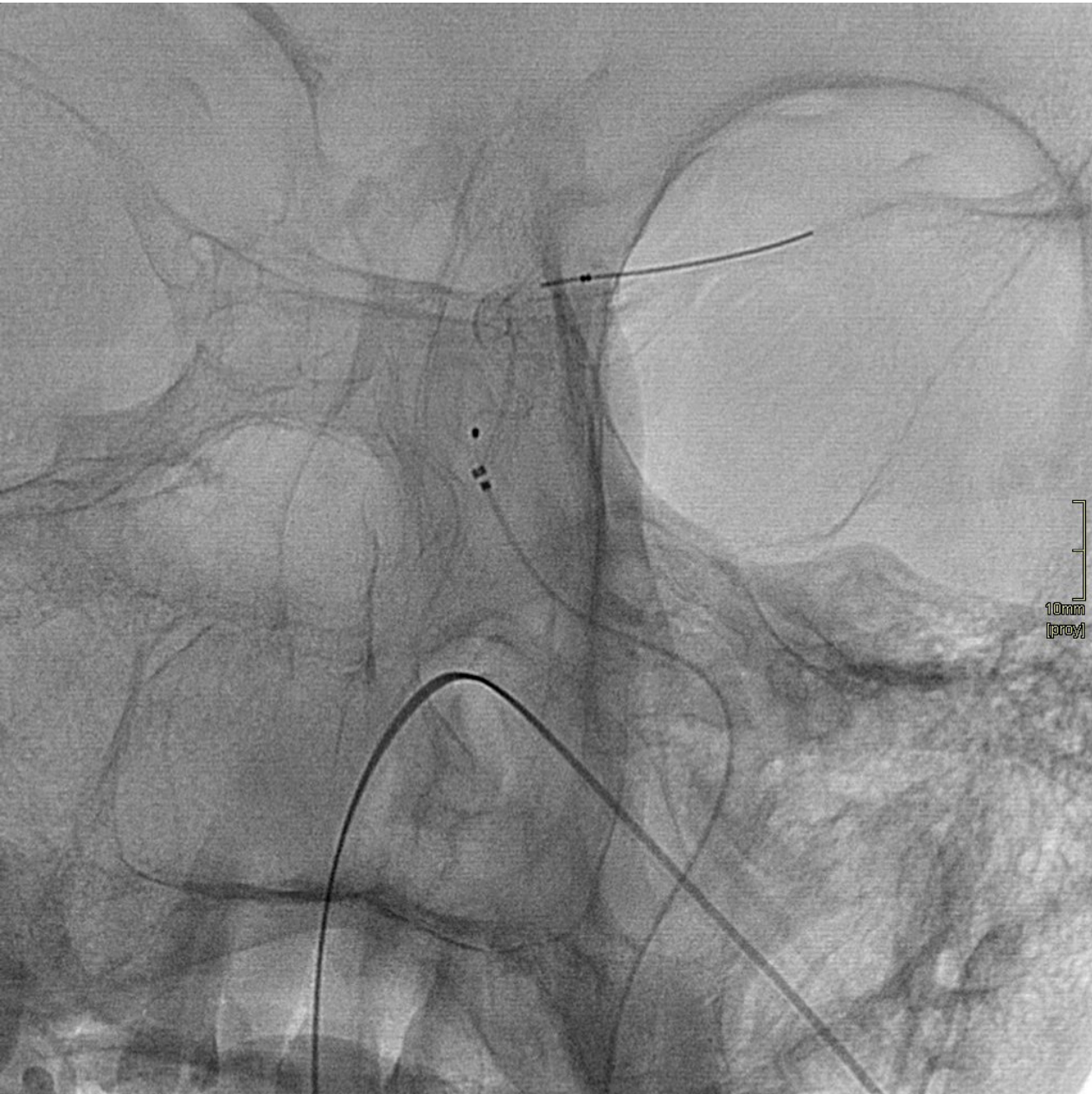
📄 19:91
🕒 0:04
📅 11:44:33

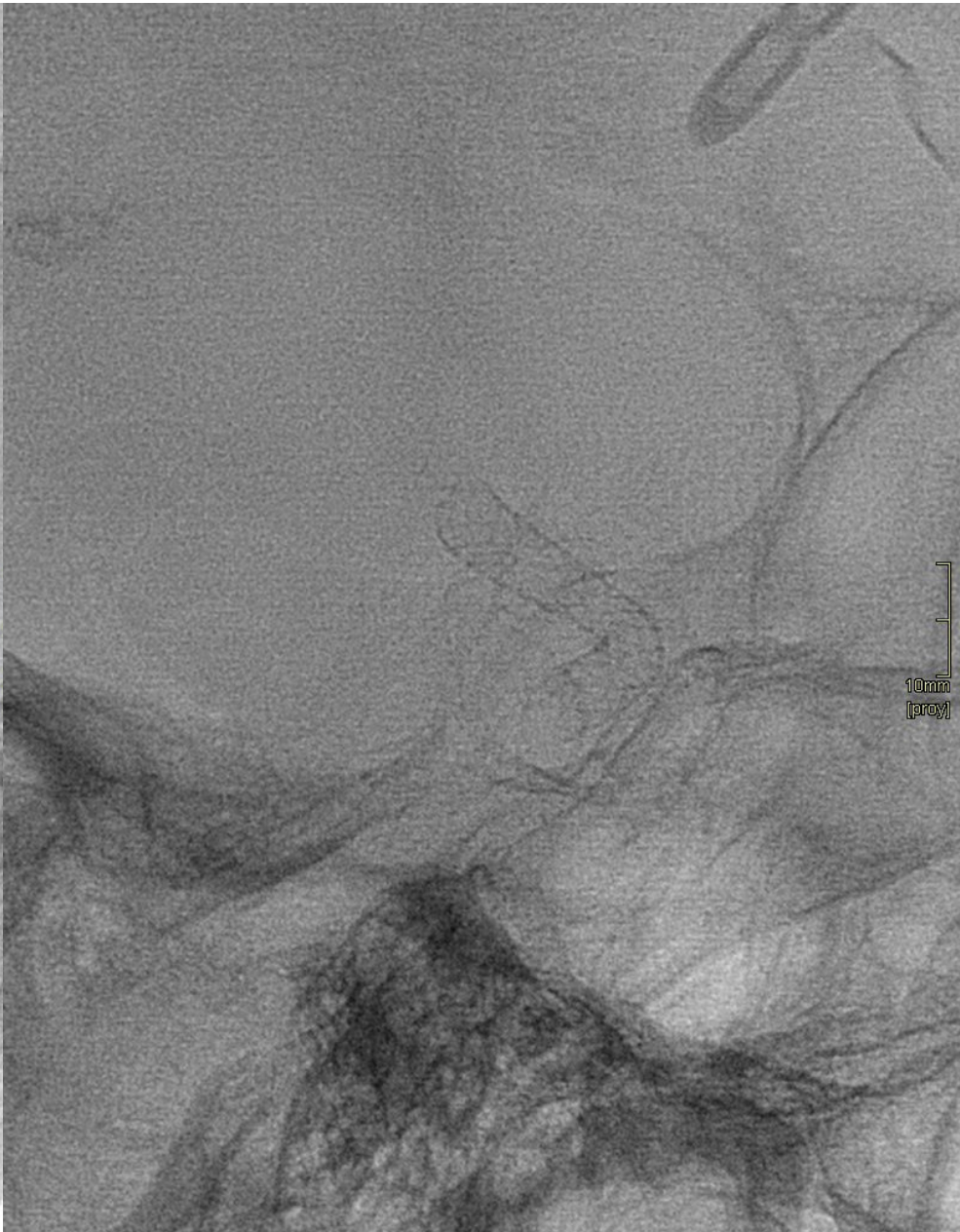
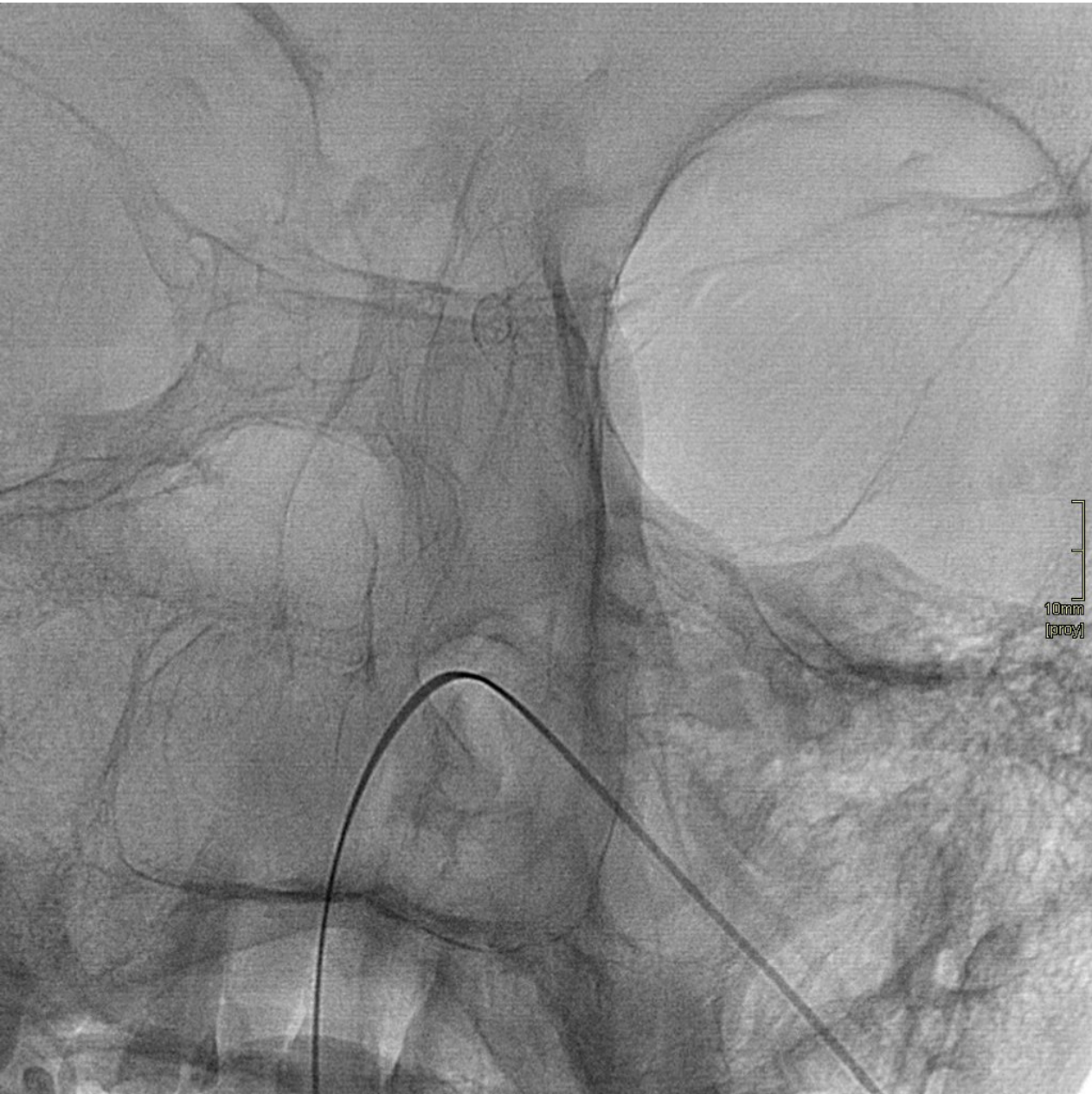
19
299-1



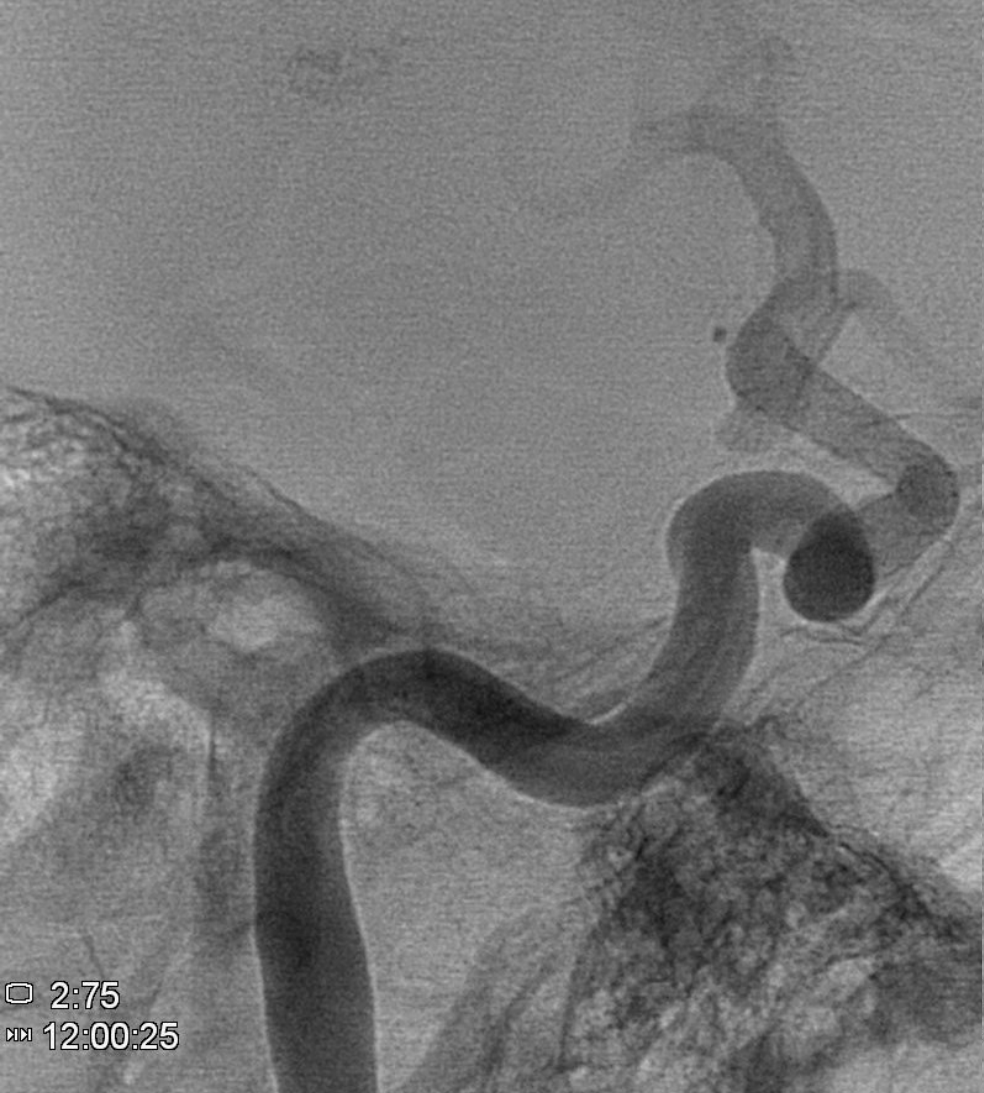






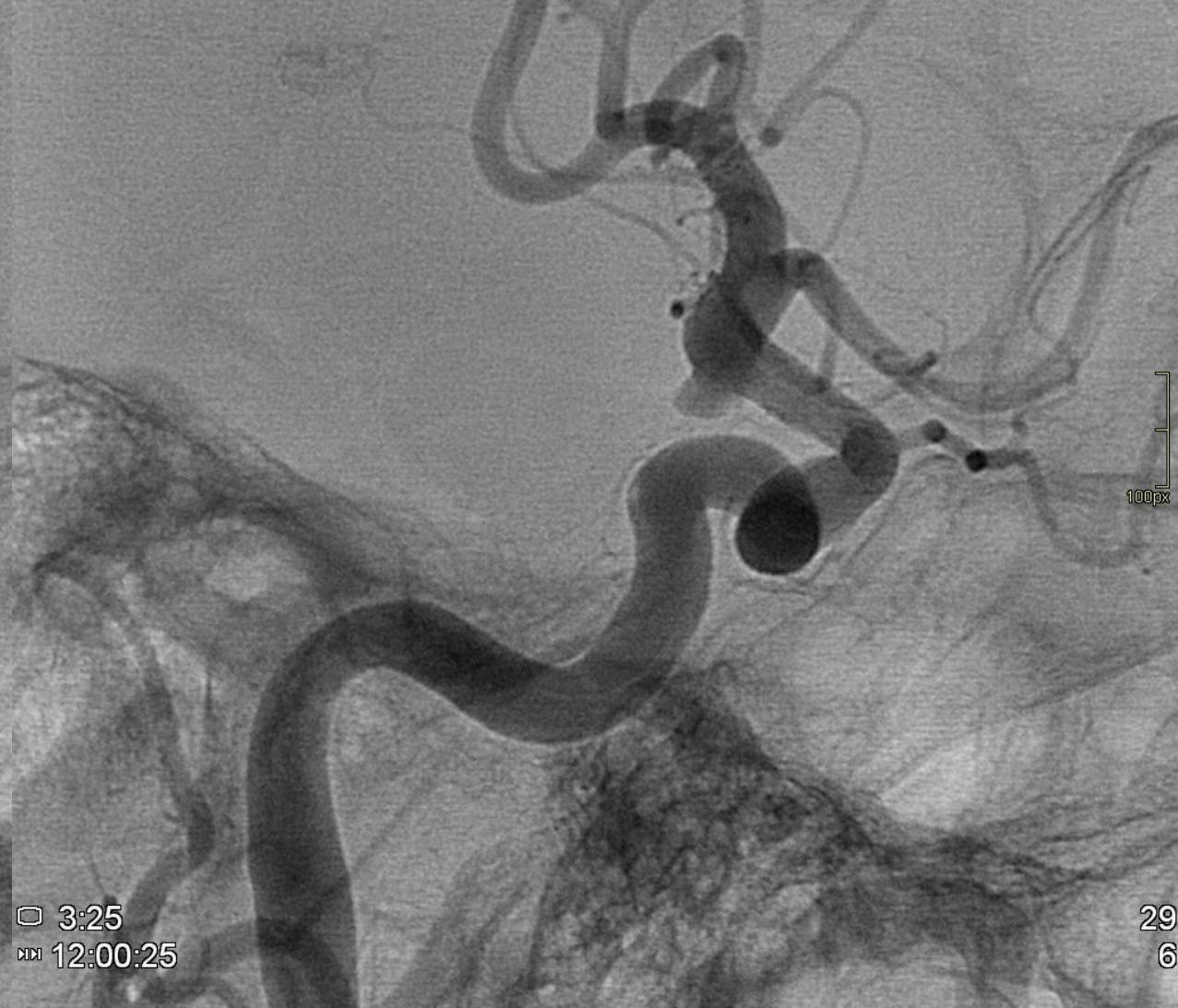
Rot -115°
Áng -22°
FD 15 cm



□ 2:75
MM 12:00:25

Rot -115°
Áng -22°
FD 15 cm



□ 3:25
MM 12:00:25

100px

29
6